ISSN 1454-7406

UNIVERSITATEA DE ŞTIINȚE AGRICOLE
ŞI MEDICINĂ VETERINARĂ
„ION IONESCU DE LA BRAD” IAŞI

# LUCRĂRI ŞTIINȚIFICE
# VOL. 52(11)

# MEDICINĂ VETERINARĂ

PARTEA 1/2

EDITURA „ION IONESCU DE LA BRAD”

IAŞI - 2009

Volumul a fost editat cu sprijinul financiar al
Ministerului Educației, Cercetării și Inovării

## COLEGIUL DE REDACȚIE

**Redactor responsabil:**
Prof. dr. SOLCAN Gheorghe

**Redactor adjunct:**
Prof. dr OPREAN Octavian Zaharie

**Membri:**
Prof. COTEA Corneliu
Conf. dr. VULPE Vasile
Prof. CARP-CĂRARE Mihai
Prof. DRUGOCIU Dan

## COMISIA DE REFERENȚI ȘTINȚIFICI

**Prof. dr. OPREAN Octavian**
**Prof. dr. H.C. CRESPEAU F. L. – ENV Alfort, France**
**Prof. dr. SOLCAN Gheorghe**
**Prof. dr. MIRON Liviu**
**Prof. dr. SĂVUȚA Gheorghe**
**Prof. dr. PREDOI Gabriel – FMV. București**
**Prof. dr. GROZA Ioan Ștefan – FMV. Cluj-Napoca**
**Prof. dr. DĂRĂBUȘ Gheorghe – FMV. Timișoara**
**Prof. dr. COTEA Corneliu**
**Prof. dr. CARP-CĂRARE Mihai**
**Conf. dr. MOROȘAN Șerban – INSERM Paris**
**Prof. dr. H.C. RUNCEANU Liviu**
**Prof. dr. H.C. COȚOFAN Vasile**
**Prof. dr. ŞINDILAR Eusebie**
**Prof. dr. PERIANU Tudor**
**Prof. dr. COMAN Ioan**
**Prof. dr. VELESCU Elena**

ISSN 1454-7406

# CLINICAL, BIOCHEMICAL AND HISTOPATHOLOGICAL STUDY ON PARASITIC GASTROENTERITIS ASSOCIATED WITH CAPRINE COCCIDIOSIS: COMPARATIVE EFFECT OF TOLTRAZURIL AND PROPOLIS

**MOHAMED M. GHANEM[1*]; AFAFA D. A. MOHAMED[2]; MOHAMED Y. RAMADAN[3],**
[1]Department of Animal Medicine
[2]Department of Biochemistry
[3]Department of Parasitology
Faculty of Veterinary Medicine (Moshtohor), Benha University, 13736, Egypt.
dr.mohamedghanem@yahoo.com

*This study investigated the gastroenteritis caused by coccidial infection in domestic goats (Capra hircus) managed under three different rearing systems (intensive, semi-intensive, and extensive) at Kalubyia governorate, Egypt. Eimeria oocysts were found in 93 (66%) of the 141 faecal samples examined. Six species of Eimeria were morphologically identified; E. hirci (90.32%), E. arloingi (83.87%), E. alijevi (75.27%), E. christenseni (63.44%), E. caprina (29.03%), and E. ninakohlyakimovae (24.73%). Up to six Eimeria species were recorded form individual specimen. The infection rates and the mean number of oocyst outputs (OPG) decreased with increasing age of goats; 80% and 31758.08 for kids; 72.92% and 19543 for young; and 30.30% and 1769.92 for adult goats, respectively. For treatment study, 4 groups of kids were used, each of 5. The first group has 5 apparently healthy kids used as control (CH). The second group involved 5 naturally infected kids and left untreated (IN). The third group included 5 naturally-infected kids and treated with Toltrazuril (20 mg/kg body weight, orally for 2 weeks). The fourth group had 5 naturally infected kids treated with Propolis (1ml of 3% aqueous solution /liter of drinking water for 7 days). The result showed that Toltrazuril was highly effective as anticoccidial drug (94.33% reduction of OPG) than Propolis that moderately reduced OPG (54.66%). The efficacy of both drugs was further compared based on antioxidant assays, serum biochemical analysis and histopathological changes. There was a significant reduction ($P < 0.05$) in erythrocyte reduced glutathione (GSH), glutathione reductase (GR-ase), superoxide dismutase (SOD), catalase activities, serum albumin, A/G ratio, calcium, sodium and potassium in Eimeria-infected kids compared to control. On the other hand, significant elevations ($P < 0.05$) in serum malondialdehyde (MDA), iron and nitrate were recorded in infected animals compared to control. The total protein and phosphorus showed non-significant decrease compared to control. Propolis and Toltrazuril treatment significantly alter the serum biochemical aberrances toward the control values. However, Toltrazuril was more efficacious than Propolis as anticoccidial drug. To the best of our knowledge, this is the first investigation on goat Eimeria prevalence and treatment in Kalubyia Governorate.*

Goat is the one of the most resourceful and efficient ruminant all over the world (**Mussman, 1982**). Easy handling, independence and adaptability to living free, modest feeding requirements, good tolerance to climatic semi-arid and arid regions, and effective conversion of limited resources into meat, milk, and hides are desired factors favoring the goat as a stock animal for small-scale farmers (**Balicka-Ramisz, 1999; Harper and Penzhorn, 1999**). Accordingly, diseases affecting goats received great attention, particularly those affecting their production.

Coccidiosis is considered as one of the most economically important diseases in intensive goat industry in the world (**Opoku-Pare and Chineme, 1979; Varghese and Yayabu, 1985; Chhabra and Pandey, 1991; Jalila *et al*., 1998; Kusiluka *et al*., 1998**). Clinical coccidiosis in goats is most frequently caused by *E. arloingi* and *E. ninakohlyakimovae,* (**Koudela and Boková, 1998; Ola- Davies, 2002; Kaba *et al*., 2007**)*, E. caprina* ***(Norton, 1986;*** **Kaba *et al*., 2007***), E christenseni* (**Kusiluka *et al*., 1996; MAFF,**

**1996; Kaba *et al*., 200**7), *E. hirci* (**Ola- Davies *et al*., 2002**), and *E. alijevi* (**Kusiluka *et al*., 1996; MAFF, 1996; Ola- Davies *et al*., 2002**). Young kids often develop and show the symptoms of the disease, while the older animals are asymptomatic (**Yvore, 1984; Jalila *et al*., 1998)**. The adult goats in a herd keep their infections year- round, continually contaminating the environment with oocysts, which serve as a source of infections for young kids (**Balicka –Ramisz, 1999; El- Seify *et al*., 2003**). Unless successfully treated, these infections in young animals lead to unthriftiness and even mortalities **(Ola-Davis *et al*., 2002; Dai *et al*., 2006; Kaba *et al*., 2007, Öcal *et al*., 2007)**.

The disease pattern is influenced by a number of factors such as environmental issues, such as moisture, temperature and oxygen tension (**Kheysin, 1972**). Climatic conditions, the nature of feeding, systems of housing and bread differences (**Kusiluka *et al*., 1998**; **Harper and Benzhorn, 1999; Chhabra and Pandey, 1991**) are also important factors contributing to spread of infection. Moreover, poor hygienic conditions were found to be associated with higher intensity of coccidial infections (**Foreyt, 1990; Jalila *et al*., 1998)**.

Prevention measures are based on increase hygienic conditions and reducing stress in goat herds (**Dhollander *et al*., 2005; Kaba *et al*., 2007**). Treatment of older goats with anticoccidial drugs suppresses the passage of oocysts in their feces; consequently, reduces the risk of infection of kids. The administration of anticoccidials to young animals at the time of weaning and shipping when stress is likely prevents a disruption of the host-parasite equilibrium, with the resultant appearance of clinical signs (**Yvore 1984)**. Many anticoccidial drugs have been commercially used, of which Toltrazuril is the most common. Toltrazuril was highly efficacious in therapy of goat coccidiosis (**Balicka- Ramisz, 1999; Balicka- Ramisz *et al*., 2004; Steinfelder *et al*., 2005; Öcal *et al*., 2007**). On the other hand, Propolis, which is a sticky resinous hive product used by bees as glue in general purpose, has been used in folk medicine for long time in different nations, such as Egypt (**Hegazi, 1998**). The pharmacologically active molecules in the Propolis are flavonoids and phenolic acids and their esters, which have multiple effects on bacteria, fungi, and viruses. In addition, Propolis and its components have anti-inflammatory and immunomodulatory activities **(Castaldo and Capasso, 2002).** Although the anticoccidial efficacy of Propolis against coccidia of rabbits has been reported (**Krell. 1996; El-Akabawy *et al*., 2004**), no study has ever conducted to determine its effect on caprine coccidiosis.

Lipid peroxidation is one of the best indicators of the level of reactive oxygen species (ROS) that induced systemic biological damage (**Popova and Popove, 2002**). The antioxidant system has a cellular protective action against oxidative stress of cell, organs and tissue damage that result from parasitic invasion (**Dede *et al* 2000**). It also plays a role in the protection of the phagocytic leukocytes against their own products and oxygen radicals. Reduced glutathione, an important antioxidant enzyme, reacts with peroxides to remove toxic substances and radicals, since it possesses active sulphydryl group (**Novak *et al*. 1991**). Although some investigation have revealed that parasitic infection causes change in lipid peroxidation parameters (**Kaya *et al* 2007, Cam *et al*. 2008**), data concerning lipid peroxidation parameters in Eimeria-infected goats treated with Propolis in not available. In addition, little literature is available on the efficacy of Toltrazuril on intestinal coccidiosis in goats.

Therefore, this study was carried out to determine the prevalence and oocyst burden of infections in different age categories of goats kept under different types of production systems, [intensive (modern), semi- intensive, and extensive (traditional or free range)] at three different localities in Kalubyia governorate, Egypt. Further aim was to evaluate the therapeutic efficiency of Propolis compared with that of Toltrazuril for controlling cocciadain infection in goats. The comparative efficiency was based on the OPG, the biochemical alterations in erythrocyte redox system, lipid peroxidation, nitric oxide (NO) production and serum total protein, albumin, globulin and minerals.

## MATERIALS AND METHODS

**Goats**

To determine the prevalence of caprine coccidiosis, we used a total number of 141 goats at three goat farms at Kalubyia Governorate, Egypt, where goats were managed under three different managemental systems: the intensive, semi- intensive, and extensive. Domestic goats (*Capra hircus*) were classified according to their age into three categories; kids (2-4 months), young goats [weaned but not served (5-12 months)], and adult goats (1-5 years). Data concerning the number of goats on different farms are given in **Table 1**.

*Table 1. Number of the examined goat in each age category and feeding system at Kalubyia Governorate, Egypt*

| Farm location | Management system | Kids | Young | Adult | Total |
|---|---|---|---|---|---|
| Farm 1 | Intensive | 20 | 16 | 11 | 47 |
| Farm 2 | Semi- intensive | 20 | 16 | 11 | 47 |
| Farm3 | Extensive | 20 | 16 | 11 | 47 |
| Total | | 60 | 48 | 33 | 141 |

To evaluate the treatment, twenty kids (3- to 4- month- old) were subdivided into 4 groups, each of 5. The first group involved 5 apparently healthy kids as a control (CH). The other fifteen kids were naturally infected and classified into three groups. Group 2 was left untreated as infected non-treated (IN) group. Group 3 involved animals treated with the anticoccidial drug, Toltrazuril (TT) (Baycox®, Bayer AG, LeverKusen) by oral administration at a dose of 20 mg/kg body weight for 2 weeks, according to **Balicka- Ramisz (1999)**. Group 4 included animals treated with Propolis (PT) at a dose of 1ml of 3% aqueous solution /liter of drinking water for 7 days according to **El- Akabawy *et al*. (2004)**. The efficacy of treatments was assessed on the basis of the oocyst counts, biochemical analysis and histopathological examination.

**Faecal examination and determination of OPG**

Approximately 5 grams of faecal samples were directly collected from the rectum on a monthly basis for each animal of the 141 goats, placed in labeled clean container and immediately transferred to the laboratory at the Veterinary Teaching Hospital at the Faculty of Veterinary Medicine, Benha University, Egypt for examination. Faecal examination was carried out by concentration-flotation technique according to **Pritchard and Kruse (1982)**. For every positive faecal sample, oocysts per gram of feces (OPG) were estimated by McMaster technique according to **Levine (1986).** *Eimeria* species were identified after sporulation of faeces in a thin layer of 2.5 % (w/v) potassium dichromate for one or two weeks at 25 ºC, according to **Koudela and Boková (1998).**

Identification of *Eimeria* oocysts was based on the morphologic criteria as previously described (**Soulsby 1982, Levien 1986; Minstry of Agriculture, Fisheries, and Food (MAFF, 1986)).**

**Biochemical analysis**

Blood samples were collected from jugular vein of control and infected kids. Blood samples were divided into two parts. The first part was collected in tubes containing 20 IU heparin/ml blood and was used for preparation of hemolysate after washing erythrocytes by physiological saline as described by **Kornburg and Korecker (1955)**. The hemolysate was used for determination of erythrocytic glutathione peroxidase (GSH-Px) **(Chiu *et al*., 1976),** glutathione reducatase (GR-ase),

erythrocyte reduced glutathione (GSH) **(Sedlak and Lindsay, 1968)**, superoxide dismutase (t-SOD) (**Misra and Fridovich, 1972)** and catalase **(Sinha, 1972)**. The second part of blood samples was collected in plain tubes without anticoagulant for separation of serum samples for the quantitative determination of nitrite concentration according to **Montgomery and Dymock (19**61). The malondialdehyde (MDA) was estimated spectrophotometrically using thiobarbituric acid assay. The serum was also used for determination of total protein, albumin and globulin (**Doumas and Biggs, 1972),** calcium (**Henry, 1974),** phosphorous (**Morinal and Prox, 1973**), sodium **(Gindler and King, 1972)** potassium (**El-Merzobani *et al*., 1977)** and iron (**Dreux, 1977).**

**Histopathological examination:**

Specimens were collected from the small intestine of untreated and treated kids and immediately fixed in 10% neutral buffered formalin. After proper fixation, thin paraffin sections (5-7 microns thickness) were routinely prepared and stained with hematoxylin-and-Eosin (H&E) for microscopical examination according to **Drury and Wallington (1967)**.

**Statistical analysis:**

Data were analyzed by one way analysis of variance (ANOVA) followed by Duncan's multiple range test using SPSS program (SPSS v10, SPSS Inc., Chicago, IL, USA). Data were represented by means ± standard error (SE). Means were considered significantly different when P-value < 0.05.

## RESULTS

**Prevalence of coccidian infection in goats**

A total of 93 (66%) of the 141 faecal samples taken during the study period were positive for *Eimeria* oocysts. Concerning age categories, the infection rates were 80 %, 72.92%, and 30.30% for kids, young, and adult goats, respectively. With regard to rearing systems, infections rates were 76.60%, 65.96%, and 55.32% in goats managed under the intensive, semi- intensive and extensive systems, respectively **(Table 2)**. Six species of *Eimeria* were identified in fecal samples. *E. hirci* (90.32%), *E. arloingi* (83.87%), *E. alijevi* (75.27%), and *E. christenseni* (63.44%) were predominant in all age categories, whereas *E. caprina* (29.03%), and *E. ninakohlyakimovae* (24.73%) were less common (**Table 3**). Infections with different types of Eimeria was evident within the same animal where up to 6 *Eimeria* species recovered from individual animal. Mixed infections with three and four *Eimeria* species were the most common (55.91 and 49.46%, respectively) (**Table 4**).

*Table 2. Number and percentage of coccidial infection in kids, young and adult goats at three different managmental systems at Kalubyia Governorate, Egypt*

| Management system | Number of infected goats | | | | Percentage of infected goats | | | |
|---|---|---|---|---|---|---|---|---|
| | Kids | Young | Adults | Total | Kids | Young | Adults | Total |
| Intensive | 18 | 13 | 5 | 36 | 90.00 | 81.25 | 45.45 | 76.60 |
| Semi- intensive | 16 | 12 | 3 | 31 | 80.00 | 75.00 | 27.27 | 65.96 |
| Extensive | 14 | 10 | 2 | 26 | 70.00 | 62.50 | 18.18 | 55.32 |
| Totals | 48 | 35 | 10 | 93 | 80.00 | 72.92 | 30.30 | 65.96 |

*Table 3. Percentage of each species of Eimeria infecting goats of all ages under three managemental systems (intensive, semi-intensive and extensive) at Kalubyia Governorate, Egypt.*

| Eimeria Type / Management system | E. Hirci | E. ariongi | E.alijevi | E. christen | E. caprina | E. nina |
|---|---|---|---|---|---|---|
| Intensive | 38.71% | 38.71% | 40.86% | 37.63% | 13.98% | 16.13% |
| Semi- intensive | 27.96% | 21.51% | 19.35% | 23.66% | 6.45% | 4.30% |
| Extensive | 23.66% | 23.66% | 15.05% | 2.15% | 8.60% | 4.30% |
| Totals | 90.32% | 83.87% | 75.27% | 63.44% | 29.03% | 24.73% |

*Table 4. Single and mixed infections with Eimeria species*

| Number of Eimeria species | 1 | 2 | 3 | 4 | 5 | 6 |
|---|---|---|---|---|---|---|
| Number of infected goats | 0 | 15 | 52 | 46 | 8 | 1 |
| Percentage | 0 | 16.13 | 55.91 | 49.46 | 8.60 | 1.08 |

**Clinical Signs**

Clinical coccidiosis was detected in 54.17% of kids reared mainly in the intensive system. Symptoms were poor coat, anaemia with paleness of mucous membrane (Figure 1) diarrhea (Figure 2), weight loss, dehydration, and mortality of untreated kids.

*Figure 1. Eye of Eimeria-infected kid showed pale mucus membrane*

*Figure 2. Eimeria-infected kid with soiled hind quarter and rough coat.*

PG, was highly variable among farms. The mean OPG counts were 31758.08, 19543, and 1769.92 for kids, young, and adult goats, respectively. Goats in farm 1 shed significantly ($P< 0.05$) lower oocyst counts than that of goats in other farms. OPG of kids was approximately two and eighteen times that of young and adult goats, respectively (**Table 5**).

After treatment, both Toltrazuril and Propolis significantly ($P <0.05$) reduced the oocyst outputs compared the untreated control group (**Table 6**).

*Table 5. Mean OPG in kids, young, and adult goats managed under three different feeding systems at Kalubyia Governorate, Egypt.*

| Age / Management system | Kids | Young | Adults |
|---|---|---|---|
| Intensive | 46648.25 ± 478[a] | 37661.25 ± 780 [a] | 3132.50 ± 518[a] |
| Semi- intensive | 36311.50 ± 416[b] | 14460.00 ± 442 [b] | 1412.00 ± 426[b] |
| Extensive | 12314.50 ± 357[c] | 6509.25 ± 371[c] | 765.25 ± 451[c] |

Data are presented as means ± SE

Different superscripts within the same column indicate significant difference at P> 0.05 (Duncan's multiple range test)

*Table 6. Anticoccidial efficacy of Toltrazuril and Propolis against caprine coccidiosis*

| Treatments Treatment | OPG before treatment | OPG after treatment | Reduction % |
|---|---|---|---|
| Control healthy | 0 | 0 | 0 |
| Untreated | 29798.00 ± 802[a] | 29079.800 ± 263[a] | 2.41 |
| Toltrazuril | 30124.00 ± 997 [a] | 1708.40 ± 160[b] | 94.33 |
| Propolis | 29798.00 ± 802 [a] | 13510.00 ± 200[c] | 54.66 |

Data are presented as means ± SE

Different superscripts within the same column indicate significant difference at P> 0.05 (Duncan's multiple range test).

**Biochemical changes**

There were significant reductions ($P < 0.05$) in erythrocyte GSHpx , GR-ase , SOD, and catalase activities of IN group compared to that of CH.. However, increasing in these parameters was observed after treatment, particularly with Toltrazuril. In addition, there was a significant decrease ($P < 0.05$) in erythrocyte GSH concentration of IN compared to control, which was significantly increased after treatment with Propolis and Toltrazuril . On the other hand, significant elevations in serum MDA **and** nitric oxide ($P < 0.05$) were recorded in infected animals, which had been significantly reduced after treatment with Propolis and Toltrazuril (**Table 7)**.

There was a significant decrease in the level of albumin and A/G ratio of IN kids compared to control while globulin showed a non-significant elevation compared to control group. However, treatment with Propolis and Toltrazuril significantly increased albumin and A/G ratio (**Table 8**).

*Eimeria* infection resulted in a significant reduction ($P < 0.05$) in the level of serum Ca, Na and K. These parameters were mildly increased after treatment with Propolis and Toltrazuril. On the other hand, iron was significantly increased ($P < 0.05$) in IN kids compared to control group, but decreased, albeit non-significantly, after treatment with Propolis and Toltrazuril.

*Table 7. The mean values of erythrocyte and serum antioxidant assays in Eimeria- infected kids before and 2 weeks after treatment with Propolis and Toltrazuril*

| Groups / Variables | CH | IN | PT | TT |
|---|---|---|---|---|
| GSH-px (u/gHb) | 11.59 ± 0.43$^{a}$ | 9.15 ± 0.44$^{b}$ | 9.91 ± 0.37$^{b}$ | 10.23 ± 0.25$^{b}$ |
| **GR-ase (u/gHb)** | 24.29 ± 0.43$^{a}$ | 19.21 ± 0 .51$^{c}$ | 21.12 ± 0.13$^{b}$ | 20.35 ± .36$^{b,c}$ |
| **SOD (u/gHb)** | 12.43 ± 0.26$^{a}$ | 9.59 ± 0.33$^{b}$ | 10.15 ± 0.26$^{b}$ | 9.82 ± 0.32$^{b}$ |
| **Catalase (u/gHb)** | 19.31 ± 0.21$^{a}$ | 15.78 ± 0.15$^{b}$ | 15.93 ± 0.22$^{b}$ | 16.42 ± 0.26$^{b}$ |
| **GSH (umol/gH)** | 64.53 ± 3.81$^{a}$ | 42.66 ± 3.53$^{b}$ | 57.15 ± 4.25$^{a}$ | 51.44 ± 4.37$^{a,b}$ |
| **MDA (umol/L)** | 0.63 ± 0.26$^{c}$ | 0.83 ± 0.35$^{a}$ | 0.71 ± 0.28 $^{a,b}$ | 0.74 ± 0.29$^{b}$ |
| **Nitrite (umol/L)** | 1.57 ± 0.45$^{a}$ | 2.86 ± 0.22$^{b}$ | 2.05 ± 0.11$^{c}$ | 2.13 ± 0.10$^{c}$ |

CH = control healthy, IN = infected non-treated, PT = Propolis -treated, TT = Toltrazuril -treated

Data are presented as means ± SE

Means within the same column followed by different superscripts are significantly different at P > 0.05 (Duncan's multiple range test)

*Table 8. Protein and electrolyte profile in control and Eimeria-infected kids before and 2 weeks after treatment with Propolis and Toltrazuril*

| Groups / Variables | CH | IN | PT | TT |
|---|---|---|---|---|
| Total protein (gm/dl) | 6.10 ± 0.41$^{a}$ | 5.25 ± 0.49$^{a}$ | 5.71 ± 0.21$^{a}$ | 5.92 ± 0.15$^{a}$ |
| Albumin (gm/dl) | 3.48 ± 0.57$^{a}$ | 2.32 ± 0.55$^{c}$ | 2.89 ± 0.23$^{b}$ | 3.14 ± 0.14$^{a,b}$ |
| Globulin (gm/dl) | 2.63 ± 0.35$^{a}$ | 2.93 ± 0.49$^{a}$ | 2.82 ± 0.24$^{a}$ | 2.79 ± 0.28$^{a}$ |
| A/G ratio | 1.36 ± 0.17$^{a}$ | 0.86 ± 0.11$^{b}$ | 1.04 ± 0.16$^{a,b}$ | 1.12 ± 4.6$^{a,b}$ |
| Ca (mg/dl) | 10.84 ± 0.70$^{a}$ | 9.63 ± 0.13$^{c}$ | 9.81 ± 0.11$^{b,c}$ | 10.11 ± 0.18$^{b}$ |
| P (mg/dl) | 6.43 ± 0.29$^{a}$ | 5.61 ± 0.33$^{a}$ | 5.73 ± 0.22$^{a}$ | 5.86 ± 0.14$^{a}$ |
| Na (mmol/L) | 142.85 ± 8.58$^{a}$ | 115.28 ± 6.58$^{b}$ | 119.13 ± 5.28$^{b}$ | 118.94 ± 3.78$^{b}$ |
| K (mmol/L) | 6.50 ± 0.13$^{a}$ | 5.65 ± 0.22$^{b}$ | 5.76 ± 0.22$^{b}$ | 5.89 ± 0.16$^{b}$ |
| Iron (ug/dl) | 144.37 ±10.60$^{b}$ | 176.48 ± 10.06$^{a}$ | 161.33 ± 8.19$^{a,b}$ | 160.01 ± 7.24$^{a,b}$ |

CH = control healthy, IN = infected non-treated, PT = Propolis -treated, TT = toltrazurol-treated . Data are presented as means ± SE

Means within the same row followed by different superscripts are significantly different (P > 0.05, Duncan's multiple range test).

**Histopathological changes**

Microscopically, the intestinal mucosa of the untreated kids was characterized by hypertophy of the intestinal villi that were severely infected with large number of the developmental stages of *Eimeria* species (Figure 3). Such stages were mainly schizonts, macrogametocytes, and immature oocysts (Figure 4). The mucosal blood vessels were congested with blood and the lamina propria was infiltrated with leucocytes particularly lymphocytes and oesinophils. Large area of the intestinal mucosa were eroded and showing desquamation of the lining epithelia cells which seen in the intestinal lumen mixed with necrotic debris and inflammatory cells. Moreover, some areas of hemorrhages were also detected in the mucosa and submucosa of the intestinal wall.

The intestine of the Propolis-treated kids revealed focal infection of the intestinal mucosa which were well-demarcated from the adjacent normal tissue by inflammatory cells (Figure 5). The infected area revealed focal aggregation of oocysts mixed with necrotic tissue and infiltrated with lypmohcytes, macrophages, and eosinophils. The intestinal villi were moderately infected with the developmental stages of *Eimeria* particularly macrogametocytes and immature oocysts (Figure 6). Focal lymphocytic aggregations were also observed in the lamina propria of the intestinal mucosa.

Histological examination of the intestine of Toltrazuril -treated kids revealed lower number of *Eimaria* developmental stages in the intestinal epithelium. The intestinal mucosa appeared normal and muocsa of the intestinal villi were free form the developmental stages of *Eimeria* species, while only few cells were still infected (Figure 7). Moreover, regeneration of the intestinal mucosa was evidenced by hyperplasia of the epithelial cells with intestinal lymphocytic infiltration.

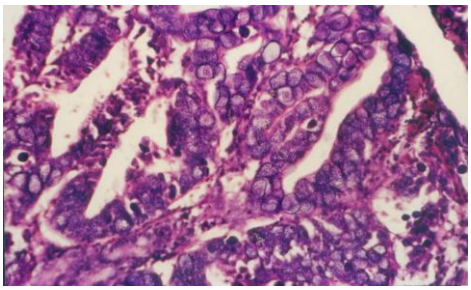

***Figure 3**. A photomicrograph showing high degree of Eimeria oocyste infestation in untreated kid*

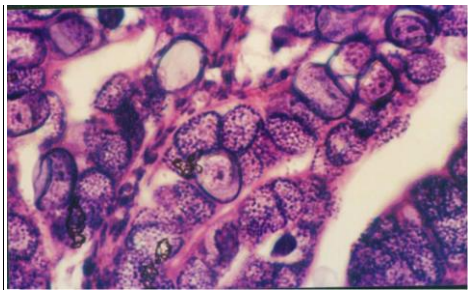

***Figure 4**. A photomicrograph showing heavy infection with schizonts and macrogametocytes of Eimeria in untreated kid*

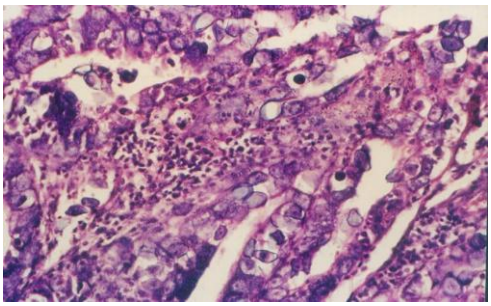

***Figure 5.** A photomicrograph of histopathological section of intestine of a kid from Propolis-treated group showing moderate number of macrogametocytes and immature oocysts in serosal layer.*

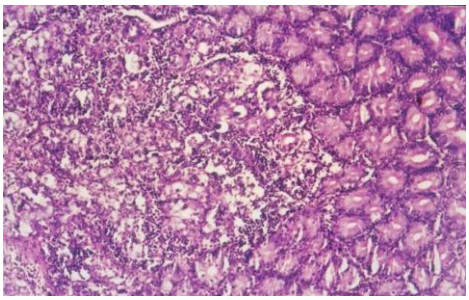

***Figure 6**. A photomicrograph of histopathological section of intestine of a kid from Propolis-treated group showing focal aggregation of oocysts separated by lymphocytes and some eosinophils that replaced the necrotic crypts of Lieberkuhn.. The adjacent mucosa appeared normal as it were uninfected.*

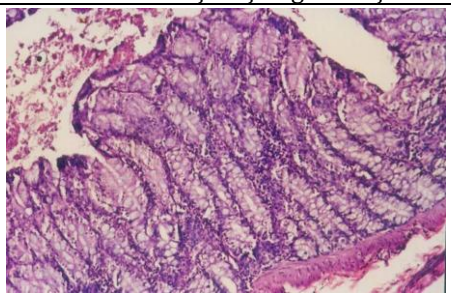

***Figure 7.*** *A photomicrograph of histopathological section of intestine of a kid from Toltrazuril-treated group showing lower degree of infection with Eimeria.*

## DISCUSSION

Coccidiosis is one of the most economically important diseases causing parasitic gastroenteritis of goats worldwide **(Foreyt, 1990; Jalial *et al*. 1998; Koudela and Boková 1998; Öcal *et al*. 2007).** The prevalence and identity of the goat coccidia in Kalubyia Governorate, Egypt, has not been previously reported. The present study indicated that *Eimeria* oocysts were found in 66% of 141 samples. The prevalence of coccidiosis was comparable to those reported in Poland (55%) (**Kaba *et al*. 2007**) and turkey (73.6%) **(Değer *et al*. 2003**). Lower prevalences were recorded, such as 6.62% in India (Patel ***et al*., 2001**) and 28% in Kenya (**Waruiru *et al*. 2005**). On the other hand, the finding of higher prevalences, such as 94.65 %, 91.5%, 93.7%, and 93.4%, was recorded in different Egyptian Governorates **by Otify (1984), El- Manyawe (1999), Arafa (2002),** and **El- Seify *et al*. (2003)**, respectively. Worldwide, higher infection rates were recorded, such as 80- 90% (**Jalila *et al*. 1998; Balica- Ramisz, 1999; Abo- Shehada and Abo- Farieha, 2003; Gül, 2007**) and <91% (**Norton, 1986; O' Callaghan, 1989; Koudela and Boková, 1998; Harper and Penzhorn, 1999)**. The difference in the prevalence of coccidial infection among different goat flocks may be attributed to the density of animals, the hygiene and management procedures, the type of husbandry adopted (intensive, semi-intensive, or free range), the climatic condition in the farming area including rainfall, temperature, and humidity **(Abo-Shehada and Abo- Farieha, 2003)**. In addition, the coccidiosis carrier- state in the dams may be considered as the main source of infection to kids (**Balicka –Ramisz, 1999; El- Seify *et al*. 2003**).

In general, several *Eimeria* species occur simultaneously in goats (**Levine, 1986**). In the present work, six species of *Eimeria* were identified, *E. hirci* (90.32%), *E. arloingi* (83.87%), *E. alijevi* (75.27%), *E. christenseni* (63.44%), *E. caprina* (29.03%), and *E. ninakohlyakimovae* (24.73%). Species of coccidia encountered in goats in this study have also been reported in other Egyptian Governorate by **Otify (1984), Arafa (2002),** and **El- Seify *et al*. (2003)**, also they recorded 8, 8, and 15 Eimeria species, respectively. Mixed infections with different *Eimeria* species were common. This result is in agreement with other reports (**Soulsby, 1982; Foreyt, 1990; Chhabra and Pandey, 1991; Kusiluka *et al*., 1996; Koudela and Boková, 1998; Harper and Penzhorn, 1999; Değer *et al*. 2003; Gül, 2007)**. Usually, from eight (**Kusiluka *et al*. 1996**) to 16 (**Smith and Sherman, 1994**) *Eimeria* species were recorded worldwide; however, the exact number of species is usually different (**O' Callaghan, 1989**).

Analogous to our result, infection with 3 *Eimeria* species was the most common in Turkey (**Değer *et al*. 2003; Gül, 2007)**.

The pathological significance of different types of Eimeria has been documented. These species include *E. arloingi* and *E. ninakohlyakimovae* (**Levine, 1986; Kusiluka *et al*. 1996; MAFF, 1996; Koudela and Boková, 1998; Ola- Davies, 2002; Kaba *et al*. 2007)*, E. caprina* (Norton, 1986; Kaba *et al*. 2007**), *E. christenseni* (**Kusiluka *et al*. 1996; MAFF, 1996; Kaba *et al*., 2007**) *E. hirci* (**Ola- Davies *et al*. 2002**), and *E. alijev*i (**Kusiluka *et al*. 1996; MAFF, 1996; Ola- Davies *et al*. 2002**). As described by **Smith and Sherman (1994**), the pathogenicity of *E. arloingi* and *E. christenseni* is moderate to severe. In contrast, *E. ninakohlyakimovae* is considered to be the most pathogenic species (**Smith and Sherman, 1994; Taylor and Catchpole, 1994; Dai *et al*., 2006)** in goat causing severe coccidiosis. These pathogenic species may be contributing to enteric syndromes and mortalities encountered in goats in our study.

Infections in all three-age categories were observed in this study. The prevalence of coccidial infections was highest in young animals, which was similar to that reported by **Jalila *et al*. 1998; Kusiluka 1998; Balicka-Ramisz, 1999, Değer *et al*. 2003; Waruiru *et al*. 2005; Kaba *et al*. 2007; Kimbita et al. 2009.** The higher intensity of infections in kids may be attributed to the reduction of passive immunity provided by the colostrum during the first weeks **(Taylor, 1995),** the lack of acquired immunity at this young age and the current bad management of keeping young kids alongside their dams in and near the shed and thus exposing them to a higher infection level (**Jalila *et al*. 1998**; **Balicka –Ramisz, 1999; El- Seify *et al*. 2003)**. The data revealed that the oocyst counts showed a decreasing trend after 4 months of age, suggesting development of acquired immunity. Similar observation was previously reported by **Jalila *et al*. 1998**.

Another important factor contributes to the prevalence of eimeriosis in goats is the management systems. A very high prevalence and oocyst counts in this study were observed in kids reared under intensive system, when compared to that reared under extensive system. In an agreement with this result, clinical coccidiosis was considered to be mainly a disease of young animals **(Soulsby, 1982; Foreyt, 1990; Balicka- Ramisz *et al*, 2004)** particularly those kept under intensive systems of management **(Opoku-Pare and Chineme, 1979; Varghese and Yayabu, 1985; Catchpole *et al*., 1993; Kusiluka *et al*., 1996).** Moreover, higher coccidia prevalence and oocyst counts were observed in the semi- intensive system when compared to those of the free range (**Patel *et al*. 2001**). Quite the opposite, the disease rarely occurs in less intensive systems probably because the young animals meet the parasite more gradually and able to gain effective immunity **(Catchpole el al. 1993).**

Caprine Eimeriosis caused severe pathological gastroenteritis, which is manifested clinically by poor coat, diarrhea, anaemia, weight loss, dehydration, and mortality of untreated kids. These findings were also reported by several other authors **(Koudela and Kovkova, 1998; Ola- Davis *et al*., 2002; Dai *et al*., 2006; Kaba *et al*., 2007; Öcal *et al*., 2007).** Caprine coccidiosis might be the cause of kid's mortality observed in the intensive system management as previously reported (**Ola- Davis *et al*. 2002; Dhollander *et al* 2005).** Coccidiosis causes a significant economical loss due to retarded growth and death as a consequence of dysentery and anaemia (**Gab- Allah, 1990; Jalila *et al*., 1998**), whereas survival of the remaining kids could be due to their level of resistance or immunity to the parasite (**Agyei *et al*. 2004**).

Sub-clinical infections are common in goat (**Koudela and Boková, 1998; Değer *et al*., 2003; Balica- Ramisz *et al*., 2004**). The presence of such sub-clinical level of *Eimeria* infection in goat flocks might be significant in two ways. First, infected goats can be potential carriers and may act to increase the severity of infection precipitating the disease in a susceptible group of kids **(Jalila *et al*., 1998).** Second, sub-clinical *Eimeria* infection alone or with concurrent gastrointestinal nematodes may negatively influence the weight gain of goats **(Faizal *et al*., 1999).** The absence of clinical symptoms of coccidiosis may be attributed to the species of *Eimeria* involved in the disease (**Jalila *et***

***al*., 1998**), the level of hygiene (**Foreyt 1990; Jalila *et al*. 1998**), and the type of management system **(Jalila *et al*., 1998**). On the other hand, clinical coccidiosis often occurs when oocyst counts are very high (**Yvore, 198**4**; Soulsby, 1982**) with over 5000 OPG being significant in ruminants (**Radostits et al. 2007**). Additionally, **Norton (1986)** demonstrated that kids showing clinical signs when excreting up to 36, 000 oocysts per gram of faeces. Although large number of oocysts were found in the feces of some kids (more than 5x $10^5$ OPG), they showed sub-clinical sings (**Koudela and Boková, 1998**). This may be support the view of **Taylor and Catchpole (1994)** that the level of oocyst output is not important in determining the severity of eimeriosis.

Because caprine eimeriosis has a great economical impact, treatment of this disease represents a challenge because of the reinfection. Toltrazuril was highly efficient in treatment of caprine coccidiosis as it produces 94.33% reduction of the mean OPG, a result that was consistent to that recorded by **Balicka- Ramisz (1999); Balicka- Ramisz *et al*. (2004)**. Moreover, treatment with Toltrazuril terminated the ongoing disease and did not interfere with the establishment of protective immunity against challenge infections (**Steinfelder *et al*. 2005). Öcal *et al*. (2007)** added that oral administration of Toltrazuril at a dose of 25 mg/kg/day for two consecutive days provided an effective treatment for acute clinical coccidiosis in goat kids and such dose did not result in acute liver and kidney damage.

On the other hand, Propolis decreased OPG by 54.66% and stopped diarrheas. Treated goats presented no behavioral signs of toxicity and the palatability of the drinking water was not reduced by the presence of Propolis. It has been demonstrated that Propolis was also effective against other protozoa species, such as *Eimeria stiedae* **(El- Akabawy *et al*. 2004**), *Giardia duodenalis* (**Freitas *et al*. 2006**), *Trypanosoma cruzi* (**Dantas *et al*. 2006**), and *Leishmania* species **(Duran *et al*. 2008).** Propolis is an old remedy used in modern medicine. It is one of the few natural remedies that have got its popularity over a long period. In veterinary medicine, Propolis is used to heal wounds, in weight gain programs for unweaned calves and egg-laying hens, and in the treatment of much pathology, such as diarrhoeas, abscesses, burns, dermatosis, mastitis, coccidiosis, and *Eimeria* in rabbits (**Krell, 1996**). Besides, extracts of Propolis are non toxic in experimental animals (**Kleinrok *et al*. 1978**). In addition, Propolis has an immunomodulatory activity (**Castaldo and Capasso, 2002; Sforcin *et al*. 2002**) on the host's specific (**Sá-Nunes *et al*. 2003**) and non-specific immunity (**Orsi *et al*. 2000; Sá-Nunes *et al*. 2003**) which occurs through macrophage activation (**Orsi *et al*. 2000**). Additionally, there were no significant differences related to the seasonal effect on the immunomodulatory action of Propolis (**Sforcin *et al*. 2002**). The antimicrobial properties of Propolis is possibly attributable to its high flavonoid content (**Kleinrok *et al*. 1978; Castaldo and Capasso, 2002).**

Caprine eimeriosis was associated with changes in the antioxidant assays. The significant decreases ($p < 0.05$) in erythrocyte GSH-px, SOD and catalase activities were similar to the data reported by **Cam et al. (2008).** The significant decrease in erythrocyte antioxidant enzyme activities including GSH-px, SOD and catalase of *Eimeria*-infected kids could be attributed to the release of excessive free radicals during the infection or the decrease in production of these enzymes as a result of liver damage. These radicals are of parasitic origin as confirmed by **Georgieva *et al*. (2006)**. The present data also demonstrated a significant decrease ($P < 0.05$) in erythrocyte GSH and GRase activity, of infected animals. Similar results were obtained by **Georgieva *et al*. (2006)** who recorded changes in lipid peroxidation as well as altered the activities of antioxidant enzyme in the blood of chicken infected with *Eimeria tenella*. The decreased values of GSH of infected goats indicated the oxidative damage due to generation of $H_2O_2$ by various mechanisms **(Gibson *et al*. 1980)**. The librating free radicals resulted in the formation of protein peroxide and inactivation of detoxifying enzymes, such as GSH-Px via splitting of peptide chain **(Pigeolet and Ramacele 1991)**. The recorded significant increase in the lipid peroxidation came in accordance with **Dede *et al* (2002**) who reported that the parasites, such as *Trichostronglylida* sp., *Eimeria* sp. and *Babesia* sp. in kids induced lipid peroxidation due to increased ROS generation to an extent that overcomes the cellular

antioxidants resulted in oxidative stress **(Mates 2001)**. In addition, there is increased production of aldehydic compounds such as MDA, which is considered one of the bio-products in lipid peroxidation and a marker of oxidative stress **(Lee *et al*. 2004).** The significant increase in the nitrate in *Eimeria*-infected goats was similar to the results of **Dede *et al*. (2002)** who concluded that the elevated level of nitrate concentration in serum of goats infected with parasites is a result of damage caused by invasion, suggesting that parasitic infection has direct effect on nitrate level.

Regarding the effect of *Eimeria* infection on protein profile, the noticed hypoalbuminemia could be attributed to the diarrhea caused by parasitic gastroenteritis caused by Eimeria infection (**Bangoura *et al* 2007)**. In general, diarrhea causes intestinal protein loss and consequently reduces serum total protein and albumin concentration due to increased intestinal protein loss and malabsorption after moderate Eimeria infection.

The changes in mineral concentrations in this study were in agreement with those reported by **Bangoura *et al*. (2007)** who concluded that coccidiosis in calves causes diarrhea with subsequent systemic acid-base and electrolyte imbalance. The observed hypocalcaemia could be attributed to the reduction of non-diffusible albumin bound fraction **(Coles 1986)**. Generally, the level of minerals decreased due to anorexia and fluid loss as well as decreased absorption of calcium and other minerals from the intestine due to diarrhea **(Stemrmer *et al*. 1991)**. On the other hand, the present data revealed a significant increase of serum iron of *Eimeria*-infected goats, which could be attributed to the blood haemolysis induced by parasites because of the release of free radicals invading erythrocytes leading to destruction of their membranes **(Itoh and Itoh, 1992).**

The recorded significant increase in GSH of *Eimeria*-infected kids after 2 weeks of treatment with Propolis agreed with **Uzbekova *et al*. (2001**) who demonstrated a reduction of MDA content in blood and liver and an increase of GSH content in the rat liver by 83.3%. This result may be attributed to the antioxidant properties of Propolis which has been shown to inhibit both lipooxygenase activity and suppress lipid peroxidation **(Fadillioglu *et al*. 2004**). As well as maintenance of cellular reduced glutathione (GSH) content which play an important role in conserving the integrity of biomembranes **(El-Khatib *et al*. 2002)**. It was reported that Propolis supplement modulated antioxidant enzymes and significantly decreased lipid peroxidation processes in plasma, liver, lungs and brain of mice **(Sobocanec *et al*. 2006).** In addition**,** treatment of naturally *Eimeria*-infected kids with Propolis reduced the nitrate, which was similar to that previously reported (**Fuliang, 2005)** who found that, following treatment with Propolis the levels of NO and NOS was decreased. This result suggested that Propolis decreases the level of NO by decreasing the output of NOS thus protecting the endothelial cells of blood vessels and reducing neuronal toxicity.

The current study also showed that Propolis improves hypoproteimemia, hypoalbuminemia and decreased the A/G ratio. These results were in complete harmony with **Murad *et al*. (2002)** who confirmed that Propolis has hepatoprotective and immunostimulating effect. The improvement of serum total protein, albumin and globulin reflects the protective effect of Propolis on hepatic injury caused by parasitic infection **(El- Akabawy *et al*., 2004).** Moreover, the relief of intestinal degeneration reflects the partial protective effects of Propolis on intestinal injury caused by *Eimeria* infection **(El-Khatib *et al*., 2002)**, which consequently improve the absorption of minerals in intestine such as Ca, P , Na and K. In addition Propolis contains protein, amino acids, vitamins, flavinoid and minerals such as Ca, P, Mg, k, iron, copper, cobalt and zinc; **(Walker and Grane 1987)** that may play a part in improvement of mineral levels**.** It was also demonstrated that the addition of Propolis to the diet improves the digestive utilization of iron and regenerate efficiency of hemoglobin **(Haro *et al*. 2000).**

Regarding the Toltrazuril -induced changes in the anti-oxidant assays, our data were in agreement with **Gokhan *et al* (2004)** who reported that Toltrazuril administration increased antioxidant enzyme activities in erythrocytes of poultry. In contrast MDA level showed a significant decrease in the group which received Toltrazuril following *Eimeria* infection. This result was

confirmed by **Cam et al (2008)** who concluded that treatment with Toltrazuril was highly effective in reducing fecal oocyst output in *Eimeria* infected rabbit as well as modulate biochemical and lipid peroxidation parameters to be close to the level of control group. Toltrazuril had also a good prophylactic effect reflect on biochemical serum analysis via improvement of hypoproteinemia, hypoalbuminemia (**Mohamed, 2002).** In addition**,** the recorded results displayed that oocysts reduction percent. under treatment with Toltrazuril was 94.7%; thusl it is highly effective against all intracellular stages of *Eimeria* **(El-Akabawy *et al*. 2004)** and consequently improves most biochemical parameters including serum minerals and erythrocyte antioxidant enzyme.

The major histopathological changes observed in this study were identical to those described by many other authors (**Jubb *et al*. 1985; Gab Allah 1990; Koudela and Boková, 1998; and Öcal *et al*. 2007).** Lower number of *Eimeria* developmental stages and presence of regenerated mucosa were observed in Toltrazuril -treated kids. Toltrazuril was efficient against schizonts and microgametes of coccidia strains in poultry **(Sreter *et al* 1999).** On the other hand, the therapeutic effect of Propolis could be attributed to stimulation of the local immune reaction resulting in elimination of most developmental stages of *Eimeria.* Moderate number of macrogametocytes and immature oocysts were focally observed in the intestinal epithelium of Propolis -treated group. Furthermore, absence of intestinal degeneration reflects the partial protective effect of Propolis on intestinal injuries caused by eimeriosis. Propolis induced similar observation in hepatic tissues **(El- Akabawy *et al*., 2004)**.

## CONCLUSION

It could be concluded from this study that *Eimeriosis* is a widespread disease among goats at kalubyia Governorate, Egypt. The disease showed age and management-related variations in oocyst outputs with special clinical and pathological significance in kids under intensive management. The use of Propolis and Toltrazuril seems beneficial in reduction of oocyst production and amelioration of disease-associated biochemical and histopathological changes, although Toltrazuril was more efficient in reducing the OPG.

## REFERENCES


1. Abo-Shehada, M.N., Abo-Farieha, H.A., 2003. Prevalence of Eimeria species among goats in northern Jordon. Small Rum. Res. (49) 109- 113.
2. Agyei, A.D., Odenkor, M., Osei- Somuah, A., 2004. Occurrence of Eimeria and helminth parasitc infections in West African Dwarf Kids in Ghana. Small Rumin. Res. (51) 29-35.
3. Arafa, M., 2002. Studies on coccidiosis in goats. Assuit . Vet. Med. J. 46 (92): 213- 223.
4. Aydogan, H., Gurlek, A., Parlakpinar, H., Askar, I., Bay Karabulut, A., Aydogan, N., Fariz, A., Acet, A., 2007. Beneficial effects of caffeic acid phenethyl ester (CAPE) on the ischaemia reperfusion injury in rat skin flaps. J. Plast., Reconstr Aestht. Surg. (60) 563-568.
5. Balicka- Ramisz, A., 1999. studies on coccidiosis in goats in Poland. Vet. Parasitol. (81) 347-349.
6. Balicka-Ramisz, A., Pilarczyk, B., Osipowic, V.S., 2004. The course and control of coccidiosis in goats. Ann. Anim. Sci. 4(1): 173-179.
7. Bangoura, B., Daugschies, A., Fuerll, M., 2007. Influence of experimental Eimeria Zuernii infection on clinical blood chemistry in calves. Vet. Parasitol. (150) 46- 53.
8. Cam, Y., Atasever, A., Erslan, G., Kibar, M., Atalay, O., Beyaz, L., Inci, A., Liman, B.C., 2008. Eimeria steidae : Experimental infection in rabbits and the effect of treatment with Toltrazuril and ivermectin. Experimental parasitology (119) 164-172.
9. Castaldo, S., Capasso, F., 2002. Propolis , an old remedy used in modern medicine. Fitoterapia (73) 1-6.
10. Catchpole, J., Norton, C.C., Gregory, M.W., 1993. Immunization of lambs against coccidiosis. Vet. Rec. (132) 56–59.
11. Celik, O., Turkoz, Y., Hascalik, S., Hascalik, M., Cigremis, Y., Mizrak, B., 2004. The protective effect of caffeic acid phenethyl ester on eschemia reperfussion onjury in rat ovary. Eur. J. Obstet. Gyn. R. B, 117(2):183-188.
12. Challem, J., 1994. Some of the Propolis components function as antioxidant free-radical scavengers. J. Ethnopharmacol. (21) 9-13.
13. Chhabara, R.C. Pandy, A., 1991. Coccidia in goats in Zimbabwe. Vet. Parasitol. (39) 199-205.

14. Chiu, D.I.Y., Stults, F.H., Tappal, A.L., 1976. Purification and properties of rat lung soluble glutathione peroxidase. Biochem. Biophys. Acta (445) 558-566.
15. Coles, E.H., 1986. Vet. Clin. Pathol. 4th Ed. W.B. Saunders Company, Philadelphia.
16. Dai, Y.B., Liu, X.Y., Liu, M., Tao, J P., 2006. Pathogenic effects of the coccidium Eimeria ninakohlyakimovae in goats. Vet Res. Commun. (30) 149-160.
17. Dantas, A.P., Salomão, K., Barbosa, H.S., De Castro, S.L., 2006. The effect of Bulgarian Propolis against Trypanosoma cruzi. Mem. Inst. Oswaldo Cruz. (101) 207-211.
18. Dede S., Deger, Y., Kahraman, T., Deger, S., Alkan, M., Cemek, M., 2002. Oxidation products of nitric oxide and the concentrations of antioxidant vitamins in parasitized goats. Acta Vet. Brono (71) 341-345.
19. Değer, S., Abdurrahman G.L., Erol A.Y.A.Z., Kamile BÜEK., 2003. The Prevalence of Eimeria Species in goats in Van. J. Vet. Anim. Turk. Sci. (27) 439-442.
20. Dhollander, S., Kora, S., Sanneh, M., Gaye, M., Leak, S., Berkvens, D., Geerts, S., 2005. Parasitic infections of West African Dwarf goats and their Saanen crosses in a zero-grazing farming system in The Gambia. Revue d'Élevage et de Médecine Vétérinaire des Pays Tropicaux. (58) 45-49.
21. Doumas, B., Biggs, H., 1972. Standard methods in clinical chemistry. Vol 7 Academic Press New York
22. Dreux, C., 1977. Colorimetric method for determination of iron. Ann. Biol Chem. (35) 275.
23. Drury, R.A.B., Wallington, E.A., 1967. Carleton's Histological Technique. Fourth Edition. Oxford University Press. New York 432 pp.
24. Duran, G., Duran, N., Culha, G., Ozcan, B., Oztas, H., Ozer, B. (2008): In vitro antileishmanial activity of Adana Propolis samples on Leishmania tropica: a preliminary study. Parasitol Res. 102, 217- 225.
25. El- Manyawe, S.M., 1999. Intestinal protozoal infection among goats in Egypt. Vet. Med J 47 (3): 379-388.
26. El- Seify, M.A., Nasr, M. El-Bahy, N.E., Abdel- Wahab, T., El-Shahawy, I.S., 2003. Eimeria spp. Infecting goats at Kafr–El-Sheikh Governorate. Egyp.Vet. Med. Soc. Parasitol. J. 1(1) 199-211.
27. El-Akabawy, L.M., Zayan, K.A., Tantawy, A.A, Omar, R.E.M., 2004. Anticoccidial efficacy of Propolis and Toltrazuril against Eimeria stiedae in New Zealand white rabbits. Zag. Vet. Med. J. (32) 129-145.
28. El-Kattawy, A.M., 1995. Studies on some biochemical changes associated with blood parasite infection in cattle. Ph.D thesis Biochem. Dept. Zag. Univ.
29. El-Khatib, A.S., Agha, A.M., Mahran, L.G., Khayyal, M.T., 2002. prophylactic effect of aqueous Propolis extract against acute experimental hepatotoxicity in vivo. Znaturforsech (c). 57(3-4) 379- 385.
30. El-Merzobani, M.M., El-Aser, A.A., Zakhary, N.L., 1977. J.Clin. Chem. Clin. Biochem. (15) 715-718.
31. Fadillioglu E., Oztas E., Erdogan H., Yagmurca M., Sogut S., Uear M., Irmak M.K., 2004. Protective effects of caffeic acid phenethyl ester on doxorubicin-induced cardiotoxicity in rats. J. Appl. Toxicol. (24) 47-52.
32. Faizal, A.C.M., Rajapase, R.P.V.J., Jayasinglip,S.R., Rupasinghe, V., 1999. Prevalence of Eimeria and gastrointestinal nematodes and weight gains in treated goats in the dry areas of Sri lanka. Small Rumin. Res. (34) 21- 25.
33. Foreyt, W.J., 1990. Coccidiosis and cryptosporidiosis in sheep and goats. Vet. Clinics N. Am., Food Anim. Pract. (6) 655- 669.
34. Freitas, S.F., Shinohara, L., Sforcin, J.M., Guimarães S., 2006. In vitro effects of Propolis on Giardia duodenalis trophozoites. Phytomedicine. (13) 170-175.
35. Fuliang, H.U., Hepburnb, H.R., Xuana, H., Chenc, M., Dayau, A., and Radloffe, S. E., 2005. Effects of Propolis on blood glucose, blood lipid and free radicals in rats with diabetes mellitus. Pharmacol. Res. (51) 147-150.
36. Gab-Allah, M.S.A., 1990. Coccidiosis in anglo- Nobian goats in Gemmiza. Zag. Vet. J. 18(2) 204-214.
37. Georgieva, N.V., Koinarski, V., Gadjeva, V., 2006. Antioxidant status during the course of Eimeria tenella infection in broiler chickens. Vet. J. (172) 488- 492.
38. Gibson, D.D., Hornbrook, K.R., Mccay, P.B., 1980. Glutathione dependant inhibition of lipid peroxidation by a soluble heat-labile factor in animal tissues. Biochem. Biophys. Acta (620) 572-576.
39. Gindler, M., King, J.D., 1972. Amer. J. Clin. Pathol. (58) 376.
40. Gokhan, E., Cam, Y., Meryem, E., Bilal, C., 2004. Changes in malondialdehyde level and catalase activity and effect of Toltrazuril on these parameters in chicks infected with Eimeria tenella. Bull. Vet. Inst. Pulawy. (48) 251- 254.
41. Gül , A., 2007. The Prevalence of Eimeria species in goats in Iğdır. Turk. J. Vet. Anim. Sci. (31) 411- 414.
42. Haro, A., Lopez- Aliaga, I., Lisbona, F., Barrionuevo, M., Alfereaz, M.J., Campos, MS., 2000. Beneficial effect of pollen and/or Propolis on the metabolism of iron, calcium, phosphorus, and magnesium in rats with nutritional ferropenic anemia. J. Agric. Food Chem. 48 (11): 5715-5722.
43. Harper, C.k., Penzhorn, B.L., 1999. Occurrence and diversity of coccidian in indigenous, Saanen and crossbred goats in South Africa. Vet. Parasitol. (82) 1-9.
44. Hegazi A.G., 1998. Propolis an overview. J. Bee Informed (5) 22-23.
45. Senedcor G.W., 1961. Statistical Methods, 5th Ed. Iowa. State University Press, Iowa USA.
46. Henry, R.J., 1974. Harper Row Clinical Chem. New York 2nd edition, 644 pp.
47. Itoh, N. Itoh, S., 1992. Serum iron, unsaturated iron- binding capacity and total iron binding capacity in dogs with Babesia gebsoni infection. J. Japan Vet. Med. Ass. 45(12) 850-951.
48. Jalila, A., Dorny, P., Salim, N.B., Vercruysse, J., 1998. Coccidiosis infections of goats in Selangor, peninsular Malaysia. Vet. Parasitol. (74) 165-172.

49. Jubb, E.V., Kennedy, P.C., Palmer, N., 1985. Pathology of demostic animals, 3rd edition. Vol. 2 Academic press Inc., Orlando, San Diego, New york, Toronto, Montreal, Siddney, Tokyo.
50. Kaba, J., Klockiewicz, M., Osińska, B., 2007. Coccidiosis in goats. Życie Weterynaryjne. 82 (6) 497-499.
51. Kanyari, P.W., 1993 Relationship between coccidial and helminth infection in sheep and goats in Kenya Vet. Parasitol. (51) 137- 141.
52. Kaya, S., Suteu, R., Cetin, E.S., Aridogan B.C., Delibas, N., Dermirci, M., 2007. Lipid peroxidation level and antioxidant enzyme activities in blood of patients with acute and chronic fascioliasis. Int. J. of infectious diseases (11) 251- 255.
53. Kheysin, Y.M., 1972. Life Cycles Coccidia of Domestic Animals. William Heinemann Medical Books Ltd., London, 201 PP.
54. Kimbita, E.N., Silayo, R.S., Mwega, E.D., Mtau, A.T., Mroso, J.B. 2009. Studies on the Eimeria of Goats at Magadu Dairy Farm SUA, Morogoro, Tanzania. Trop Anim Health Prod DOI 10.1007/s11250-009-9310-2
55. Kleinrok, Z., Borzeck, Z., Scheller, S., Matuga, W., 1978. Biological properties and clinical application of Propolis . 10. Preliminary pharmacological evaluation of ethanol extract of Propolis . Arzneimittelforschung (28) 291-292.
56. Kornburg, A., Korecker, D., 1995. In Methods in enzymology. Acad. Press, New York, pp. 201-239.
57. Koudela, B., Boková, A., 1998. Coccidiosis in goats in the Czech Republic. Vet. Parasitol. (76) 261-267.
58. Krell, R., 1996. value-added products from beekeeping FAO Agricultural Services Bulletin No. 124 Food and Agriculture Organization of the United Nations, Rome.
59. Kusiluka L.J.M., Kambarage, D.M., Matthhewman, R.W, Harrison, L.J.S., Dabron, C.J., 1996. Coccidiosis of small ruminants in Tanzania. Small Rumin. Res. (21) 127- 131.
60. Kusiluka, L.J.M., Kambaragea, D.M., Harrisonb, L.J.S., Dabornb C.J., Matthewmanc, R.W., 1998. Prevalence and seasonal patterns of coccidial infections in goats in two ecoclimatic areas in Morogoro, Tanzania. Small Rumin. Res. (30) 85-91
61. Lee, J. Y., Lee, S. H., Kim, H.H., Ha, J.M., Lee, S.H., Ha, B.J., 2004. The preventive inhibition of chondroition sulfate against the CC14-induced oxidative stress of subellular level. Arch. Pharm. Res. 27(3) 340-345.
62. Levine, N.D., 1986. The protozoan Phylum Apicomplexa, vol. 2. CRC Press, Boca Raton, FL, USA (Chapters 10 and 11).
63. Lima, J.D., 1980. *Eimeria caprovina* species from the domestic goats (*Capra hircus)* from the USA. J. Protozool. (27) 153-154.
64. Morinal, L., Prox, J., 1973. New rapid procedure for serum phosphorus using o-phenylme as reluctant. Chin. Chem. Acta (46) 113-117.
65. Mates M., 2001. Effects of antioxidant enzymes in the molecular control of reactive oxygen species in toxicology. Toxicology (153) 84-104.
66. Ministry of Agriculture, Fisheries and Food, (MAFF), 1986. Manual of Veterinary Parasitological Laboratory Techniques. Reference Book 418. Her Majesty's Stationery Office, London, 159 pp.
67. Misra, H.P. Fridovich, S., 1972. The role of superoxide anion in the oxidation of epinephrine and a sample assay for super oxide dismutase. J. Biol.Chem. (247) 3170- 3175.
68. Mohamed, E.A.M., 2002. Clinicopathological studies studies on the immunity status post infestation with hepatic coccidiosis in rabbits M.V.Sc. Zag. Univ.
69. Montgomery, H.A.C. Dymock, J.F., 1961. Coloremetric method for determination of nitrite. Analyst. (86) 414.
70. Murad, J.M., Calvi, S.A., Soares, A.M., Bankova, V., Sforcin, J., 2002. Effect of Propolis from Brazil and Bulgaria on fungicidal activity of macrophages against Paracoccidioides brasiliensis. J. Ethnopharm. (79) 331- 334.
71. Mussman, H.C., 1982. The animal as food resource for man with special reference to the role of animal disease. In: Proceedings of the Third International Conference On Goat Production and Disease. Tucson, AZ, Dairy Goat J., pp. 9–14.
72. Muwalla, M.M., Abo-Shehada, M.N., Tawfiq, F., 1994. The effect of Monensin on daily gain, and natural coccidial infection in Awassi Lambs. Small Rumin. Res. 13: 205-209.
73. Norton, C.C., 1986. Coccidia of domestic goats. Capra hircus with notes on Eimeria ovinoidalis and E. bakuensis (E. ovina ) from the sheep Ovis aries Vet . Parasitol. (92) 279- 289.
74. Novak, Z., Nemeth, I., Gyurkovics, K., Varga, S.Z., Matkovics, B., 1991. Examination of the role of oxygen free radicals in bronchial asthma in childhood. Clinica Acta. (202) 247-252.
75. O'Callaghan, M.G., 1989. Coccidia of domestic and feral goats in South Australia Vet. Parasitol. (30) 267-272.
76. Öcal N., Yagci, B.B., Duru, S.Y., Kul, O., 2007. Toltrazuril treatment for acute clinical coccidiosis in hair goat kids: clinical, pathological, haematologic and biochemical findings. Medycyna Wet. 63 (7) 805.
77. Ola-Davies, O.E., Oyeyemi, M.O., Saba, A.B., and Ajala, O.O., 2002. Prevalence of Eimeria oocysts in West African Dwarf goats at the University of Ibadan farm. Nigerian J. Anim. Prod. (29) 259- 263.
78. Opoku-Pare, G.A., Chineme, C.N., 1979. Pathology of acute intestinal coccidiosis in young goats. Bull. Bull. Anim. Hlth. Prod. Afri. (27) 269- 273.
79. Orsi, R.O., Funari, S.R.C., Soares, A.M.V.C., Calvi, S.A., Oliveira, S.L., Sforcin, J.M., Bankova, V., 2000. Immunomodulatory action of Propolis on macrophage activation. J. Venom. Anim. Toxins. (6) 205–219.
80. Otify, Y.Z., 1984. Studies on coccidian parasites in goats. Ph.D. Thesis, Fac. Vet. Med. Alex. Univ.

81. Patel, M.D., Nauriyal, D.S., Hasnani, J.J., and Gupta, R.S., 2001. Prevalence of gastrointestinal parasitism in goats maintained under semi-intensive and field management systems. Indian J. Vet. Med. (21) 99-101.
82. Pigeolet, E. Ramacele, L., 1991. Susceptability of glutathione peroxidase to proteolysis after oxidative alteration by peroxidase and hydroxyl radicals. free radical Biol. Med. 11: 191- 195.
83. Popova, M.P., Popov C.S., 2002. Damage to subcellular structures evoked by lipid peroxidation . Zeitschrift Fur Naturforsch (57c) 361- 365.
84. Pritchard, M.H. Kruse, G.O., 1982. The Collection and preservation of animal parasites. University of Nebraska Press, Lincoln, Nebraska. 141 pp.
85. Radostits, O.M., Gay, C.C., Hinchcliff, K.W., Constable, P.D., 2007. Veterinary Medicine: A textbook of the diseases of cattle, horses, sheep, pigs and goats. 10th Ed. Elsevier Health Sciences, Philadelphia, PA, USA, pp. 993
86. Sá-Nunes, A., Faccioli, L.H., Sforcin, J.M., 2003. Propolis : lymphocyte proliferation and IFN-gamma production. J. Ethnopharmacol. (87) 93–97.
87. Sayin, F., Dincer, S., milli, O., 1979. Ankara kecisinde Eimeria arloingi ( Marotel 1905) Martin, 1909 patogenitesi uzerinde deneysel arastirmalar. Ankara Univ. Vet. Fak. Derg. (26) 185-202.
88. Sedlak, I. Lindsay, R.H., 1968. Estimation of total protein – bound and non protein sulphydryl groups in tissues with ellman,s reagent. Anal. Biochem. (25) 192- 205.
89. Sforcin, J.M., Kaneno, R., Funari, S.R.C., 2002.Absence of seasonal effect on the immunomodulatory action of Brazilian Propolis on natural killer activity. J. Venom. Anim. (8) 19–29.
90. Sinha, A.K., 1972. Calorimetric assay of catalase . Anal. Biochem. (47) 389.
91. Smith, M.C. Sherman, D.M., 1994. Goat Medicine. Lea and febiger, Phadelphia.
92. Sobocanec, S., Sverko, V., Balog, T., Saric, A., Rusak, G., Likic, S., Kusic, B., Katalinic, V., Radic, S., Marotti, T., 2006. Oxidant/ antioxidant properties of Croatian native Propolis . J Agri. Food Chem. 54(21) 8018-8026.
93. Soulsby, E.L.J. (Ed.), 1982. Helminths, arthropods and protozoa of domesticated animals, 7th ed. Bailliere Tindall, London, 594 pp.
94. Sreter,T., Szell, Z., Varga, I., 1999. Attempted chemoprophylaxis of cryptosporidiosis in chicken using Diclazuril, Toltrazuril or garlic extract. J. Parasitol. (85) 989- 991.
95. Steinfelder, S., Lucius, R., Greif, G., Pogonka, T., 2005. Treatment of mice with the anticoccidial drug Toltrazuril does not interfere with the development of a specific cellular intestinal immune response to Eimeria falciformis. Parasitol. (97) 458-465.
96. Taylor, M., 1995. Diagnosis and control of coccidia in sheep. In Pract. (17) 172- 177.
97. Taylor, M.A. Catchpole, J., 1994. Coccidiosis of domestic ruminants. Appl. Parasitol. (35) 73-86.
98. Uzebkova, D., Makarova, V.G., Chungova, L.G., 2001. protective effect of Propolis against hepatotoxicity induced by CC14 in rats. Medical University, Russia.
99. Varghese, T., Yayabu, R., 1985. Ovine coccidiosis in Papua New Guinea. Vet. Parasitol. (39) 181- 191.
100. Walker, P., Grane, E., 1987. Constituents of Propolis . Apidologie (18) 327-334.
101. Waruiru, R.M., Mutune, M.N., Otieno, R.O., 2005. Gastrointestinal parasite infections of sheep and goats in a semi-arid area of Machakos District, Kenya. Bull. Anim. Helth. Prod. Afri. (3) 25-34.
102. Yvore, P., 1984. Les coccidioses caprines. Les Maladies de la Ch6vre. Proceedings of a Colloquium, 9-11 October 1984, Niort, France. La Colloques de I'INRA, No. 28, pp. 479-485.
103. Yvore, P., Esnault, A., Naciri, M., 1985. La coccidiose caprine. Effect de contaminations mono ou multispecifiques. Rec. Med. Vet. (161) 347-351.